

Corneal asphericity changes after implantation of single intracorneal corneal ring segment vs implantation of double intracorneal segments in the cornea for treatment of keratoconus

Rasha Mousa

Memorial institute for ophthalmic research, Giza , Egypt
Rashamoussa78@gmail.com ,+201001423742

Abstract

Aim: To compare the effect of implantation of intracorneal rings on corneal sphericity between one segment ring and double segment ring implantation in keratoconus eyes.

Setting: Memorial institute for ophthalmic research

Methods: This study is retrospective study done on 30 eyes of keratoconus patients between 2019 and 2021. Intracorneal rings were implanted in the cornea for treatment of keratoconus. The study was done on two study groups, in Group A one ring segment was implanted and in Group B two ring segments were implanted. The choice of the number, thickness and arc length of the rings were done according to Kera ring manufacture nomogram. We studied the Corneal sphericity measured by corneal asphericity coefficient (Q value) concluded from Pentacam preoperative and 6 month postoperative. Keratometric values, visual acuity and refraction of the patients were also studied preoperatively and 6 month postoperative.

Results: The changes in refraction were statistically significant before and after surgery in both groups regarding UCVA and refraction. Comparing both groups regarding sphere and cylinder refraction, we found that there was significant difference in sphere refraction pre and postoperatively ($p < 0.001$ & 0.009 respectively) and in cylinder refraction preoperatively ($p = 0.024$). The changes in Q anterior were significant in both groups. Moreover, the changes in K1, K2, K max and astigmatism values before and after ring implantation were significant in both groups. Comparing the results of K1, K2, K max and Q anterior significant difference was observed between the two groups after surgery while there was significant difference in K1 and K2 before surgery.

Conclusion: Intracorneal ring segments implantation for treatment of keratoconus either one or two rings change the anterior corneal asphericity approximating the Q anterior value to the ideal Q value (-0.46) and improve the UCVA and the BCVA of patients besides decrease the refractive sphere and cylinder values. Implantation of two rings have higher effect than implantation of one ring on approximating the Q anterior value to ideal.

Keywords: corneal asphericity, ICRS, keratoconus, Q value .

Received : 18/4/2022

Accepted : 23/5/2022

Published : 1/6/2022

Introduction:

Intracorneal ring segments (ICRS) have long been used for visual and optical rehabilitation of ectatic corneal conditions either alone or accompanied with other treatment procedures.^{1,2}In most cases it is well tolerated effective treatment with

long term improvement of refractive and keratometry measurements³. However visual satisfaction is not guaranteed in some cases in spite of reaching close to emmetropia.⁴ This visual satisfaction unpredictability is caused by the insufficiency of the lower order aberrations on which we build our choice of rings to explore the visual quality of the patients.⁵ As the corneal asphericity of the cornea is the main source of eye spherical aberrations so The corneal asphericity coefficient (i.e., Q value) should be evaluated in association of keratometric values for better assessment of the effect on visual quality⁵. Various nomograms are used as clinical guidelines depending on preoperative clinical and topographic data to determine the number, size, arc length and location of ring insertion⁶. However most of them are empirical and based on personal and clinical experiences⁷. Improvement of the current nomograms to improve predictability of refractive and visual outcome needs a lot of effort and clinical feedback is important for this to be achieved⁸.

In the current study we evaluate the results of implantation of single or double ICRS in keratoconic eyes and our purpose is to evaluate whether implantation of single ring segment will give the same effect as implantation of double ring segments on corneal asphericity.

Materials and methods:

This study is retrospective cohort study evaluating ICRS implanted in keratoconus patients done in corneal department in Memorial institute for ophthalmic research between 2019 and 2021. the study adhered to tenets of the Declaration of Helsinki.

Patients included in this study were diagnosed with progressive moderate keratoconus and were candidate for ICRS implantation according to the following criteria : intolerance to hard contact lenses, steep K reading from 48 to 52D, corneal thickness >400 at the implantation site and best corrected visual acuity >0.1 with significant refractive error. Preoperative and postoperative data after 6 months include clinical examination, uncorrected visual acuity, best corrected visual acuity, subjective refraction and corneal tomographic data produced including k readings, pachymetry and Q value analyzed from Pentacam (Oculus, Germany). the choice of the rings were done according to the kera ring manufacture nomogram.

Surgical technique:

All the cases were done by one surgeon using the mechanical procedure under topical anesthesia. The procedure was initiated by marking of the visual axis using the corneal reflex. marking of the tunnel was done using 5mm inner diameter and 1mm width tunnel marker. Incision was done at the steep axis using diamond knife

calibrated at 80% of corneal pachymetry at the insertion site. Corneal pockets were done using 180° clockwise and anti-clockwise Suarez spreader to produce ring tunnels. Kera rings then inserted intrastromal through the incision in the corneal pocket. bandage contact lens used for 24 hours. postoperative treatment included tobramycin -dexamethasone eye drops 4 times daily for 1 week and lubricant eye drops 3 times daily for 1 month.

Statistical analysis

The clinical data were recorded on a report form. These data were tabulated and analysed using the computer program SPSS (Statistical package for social science) version 20 to obtain:

Descriptive statistics were calculated for the data in the form of mean and standard deviation \pm SD for quantitative data, frequency and distribution for qualitative data.

Analytical statistics in the statistical comparison between the different groups, the significance of difference was tested using one of the following tests after establishing their non-normality by Shapiro–Wilk test of normality.

- 1- Student's t-test was used to compare mean of two groups of quantitative data of parametric and non-parametric respectively.
- 2- Mann-Whitney's Test (U test) was used to assess the statistical significance of the difference of a non-parametric variable between two study groups.
- 3- Inter-group comparison of categorical data was performed by using chi square test (X^2 -value) and fisher exact test (FET).
- 4- Paired student t-test; used for comparison between related sample.
- 5- Wilcoxon Rank test was used to assess the statistical significance of the difference of a non - parametric variable between related sample.

A P value <0.05 was considered statistically significant (*) while >0.05 statistically insignificant P value <0.01 was considered highly significant (**) in all analyses.

Results

A total number of 30 eyes of keratoconus patients were enrolled. The age of studied cases ranged from 14 to 36 years with a mean 23.85 ± 6.73 years. 50% of patients (were males and 50% were females. The studied patients were divided into two groups (group A) with one ring implanted and (group B) with two rings implanted. Demographic characteristics of the study population in both the groups were given in Table 1. Both the groups were comparable in terms of age, gender and side. There was no significant difference between the two groups regarding age, gender and side ($p > 0.05$).

Table 1. Demographic characteristics of the study groups

		group A (n=14)		group B (n=16)		p- value
		N	%	N	%	
Age (years)	Mean± SD	21.25± 6.25		26.07± 6.52		0.068 [‡]
	Range	14.0- 34.0		18.0- 36.0		
Gender	Male	9	64.3%	6	37.5%	0.272 [‡]
	Female	5	35.7%	10	33.3%	
Side	OD	8	57.1%	8	50.0%	0.980 [‡]
	OS	6	42.9%	8	50.0%	

*Student T test Mann- Whitney U test, ‡ Fischer Exact Test

In the patients treated with one ring (group A), the changes in refraction were statistically significant before and after surgery (6 months) and showed significant changes in UCVA ($P=0.003$), sphere ($p=0.027$), cylinder ($p=0.003$) and axis ($p=0.011$). In patients treated with two rings implant (group B), the UCVA, sphere refraction, cylinder and BCVA changes were statistically significant before and after surgery (6 months) (p value = 0.001, 0.002, 0.005 & 0.004 respectively).

However, comparing groups A and B regarding sphere and cylinder refraction, we found that there was significant difference in sphere refraction pre and postoperatively ($p < 0.001$ & 0.009 respectively) and in cylinder refraction preoperatively ($p = 0.024$) as shown in table 2

Table 2. Preoperative and postoperative visual and refractive parameters in the two studied groups

			group A (n=14)	group B (n=16)	p- value †
UCVA	Preoperative	Median (IQR) Range	0.10 (0.10- 0.15) 0.05- 0.20	0.10 (0.05- 0.10) 0.05- 0.30	0.102
	Postoperative	Median (IQR) Range	0.40 (0.20- 0.50) 0.10- 0.60	0.20 (0.15- 0.40) 0.10- 0.60	0.371
♦P-value (Pre/Post)			0.003**	0.001**	
Sphere	Preoperative	Median (IQR) Range	0.0 (-2.50- 0.0) -8.0- 0.50	-5.0 (-7.0- (-4.0)) -10.0- (-2.0)	< 0.001
	postoperative	Median (IQR) Range	0.0 (0.0- 0.0) -3.0- 1.0	-1.0 (-4.0- 0.0) -10.0- (-2.0)	0.009
♦P-value (Pre/Post)			0.027*	0.002**	
Cylinder	Preoperative	Median (IQR) Range	-6.0 (-6.0- (-5.50)) -8.0- (-4.0)	-4.75 (-6.0- (-3.50)) -6.0- (-3.0)	0.024
	postoperative	Median (IQR) Range	0.0 (-4.0- 0.0) -5.0- 0.0	-2.5 (-3.0- (-2.0)) -6.0- 0.0	0.354
♦P-value (Pre/Post)			0.003**	0.005**	
Axis	Preoperative	Median (IQR) Range	90.0 (72.5- 112.5) 15.0- 140.0	110.0 (30.0- 150.0) 10.0- 175.0	0.551
	postoperative	Median (IQR) Range	0.0 (0.0- 70.0) 0.0- 115.0	110.0 (0.0- 160.0) 0.0- 180.0	0.086
♦P-value (Pre/Post)			0.011*	0.657	
BCVA	Preoperative	Median (IQR) Range	0.30 (0.25- 0.5) 0.10- 0.70	0.30 (0.25- 0.5) 0.10- 0.70	0.936
	postoperative	Median (IQR) Range	0.40 (0.30- 0.50) 0.20- 0.60	0.40 (0.30- 0.50) 0.20- 0.60	0.162
♦P-value (Pre/Post)			0.150	0.004**	
size	of first ring	Median (IQR) Range	160/250 (160/200- 160/300) 120/150- 160/300	160/250 (160/200- 160/300) 120/150- 160/300	0.527
	of other ring	Median (IQR) Range	NA	160/300 (160/250- 160/300) 160/200- 160/300	NA

† Mann- Whitney U test, ♦ Wilcoxon Rank test

UCVA uncorrected visual acuity

BCVA best corrected visual acuity

In group A, the changes in K1, K2, K max and astigmatism before and after ring implantation were significant as shown in table 3. Similarly in group B, The changes in K1, K2, and K max values before and after ring implantation were significant. When comparing the results of K1, K2 and K max significant difference was observed between the two groups after surgery. (Figure 1,2,3)

Table 3. Preoperative and postoperativeparameters in the two studied groups			group A (n=14)	group B (n=16)	p- value †
K1	Preoperative	Mean± SD Range	50.92 ± 3.21 45.70- 57.40	48.29 ± 3.21 44.60- 53.50	0.048
	Postoperative	Mean± SD Range	50.45 ± 3.45 45.40- 56.0	46.56 ± 3.93 41.0- 53.20	0.016
*P-value (Pre/Post)			0.007**	<0.001**	
K2	Preoperative	Mean± SD Range	57.58 ± 3.38 51.50- 63.20	53.24 ± 4.23 47.80- 59.70	0.009
	postoperative	Mean± SD Range	55.42 ± 3.76 49.60- 63.40	49.87 ± 5.28 43.50- 58.90	0.007
*P-value (Pre/Post)			0.001**	<0.001**	
K max	Preoperative	Mean± SD Range	65.79 ± 7.74 55.60- 80.60	60.71 ± 6.55 51.0- 71.0	0.082
	postoperative	Mean± SD Range	65.03 ± 4.10 56.70- 69.90	60.26 ± 6.18 50.30- 72.0	0.038
*P-value (Pre/Post)			0.007**	<0.001**	
Astigmatism	Preoperative	Mean± SD Range	6.23 ± 2.41 1.0- 11.30	4.91 ± 1.88 1.80- 8.4	0.131
	postoperative	Mean± SD Range	4.98 ± 2.77 1.30- 9.0	3.29 ± 1.86 0.60- 7.0	0.081
*P-value (Pre/Post)			0.022**	0.322**	
Q anterior	Preoperative	Mean± SD Range	-1.50 ± 0.61 -2.71- (-0.71)	-1.15 ± 0.44 -1.95- (-0.55)	0.100
	postoperative	Mean± SD Range	-1.21 ± 0.60 -2.09- (-0.23)	-0.49 ± 0.79 -1.62- 0.64	0.019
*P-value (Pre/Post)			0.004**	<0.001**	
Q posterior	Preoperative	Mean± SD Range	-1.54 ± 0.66 -2.74- (-0.66)	-1.20 ± 0.46 -1.93- (-0.53)	0.146
	postoperative	Mean± SD Range	-1.54 ± 0.53 -2.59- (-0.99)	-1.22 ± 0.44 -1.89- (-0.39)	0.103
*P-value (Pre/Post)			0.625	0.847	

† Student T test, *Paired T test

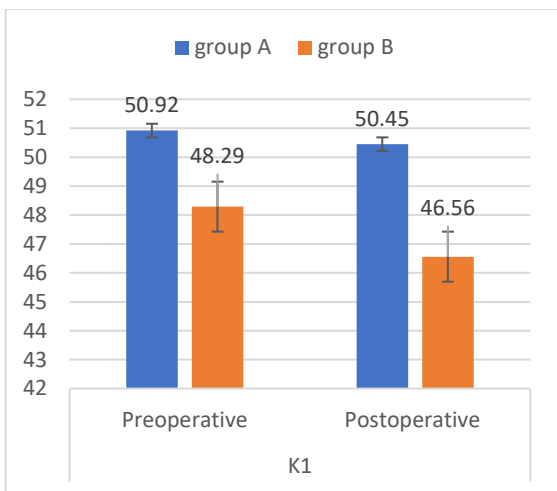


Figure (1): Comparison between the study groups regarding K

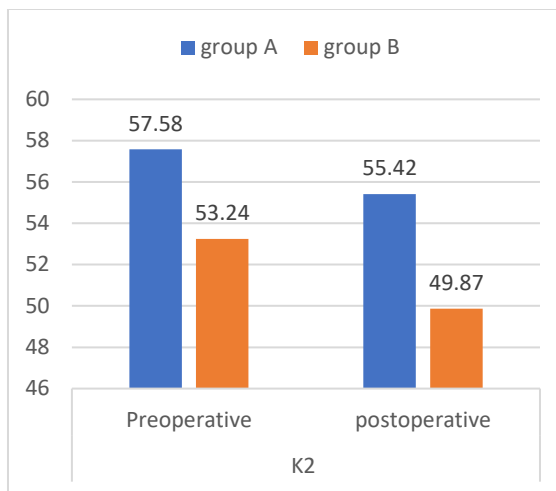


Figure (2): Comparison between the study groups regarding K2.

The changes in Q posterior before and 6 months after the operation were not significant ($p > 0.05$) in both groups. (Figure 4)

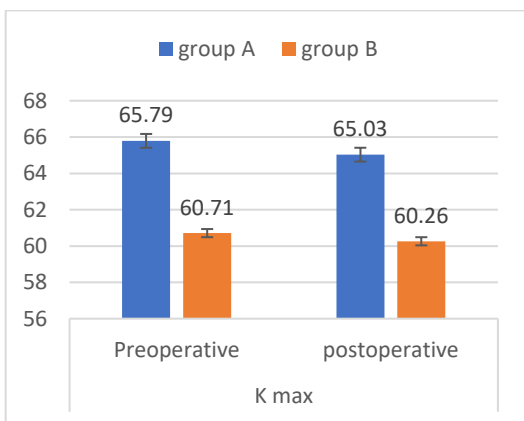


Figure (3): Comparison between the study groups regarding Kmax.

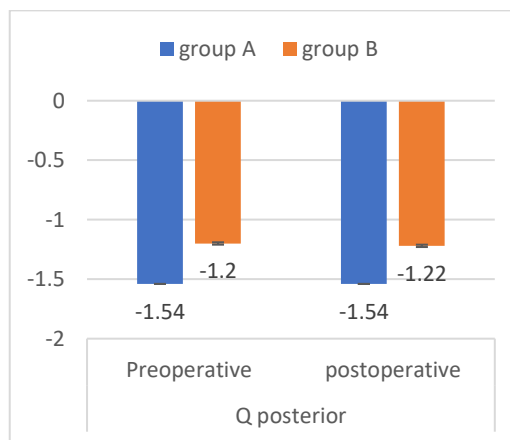


Figure (4): Comparison between the study groups regarding Q posterior

The changes in Q anterior in group A postoperative were significant ($p < 0.001$) with Mean \pm SD (-1.21 ± 0.60) and the changes in Q anterior in group B were also significant ($p < 0.001$) with Mean \pm SD (-0.49 ± 0.79) with greater changes in Group B toward normalization of corneal asphericity index. (Figure 5)

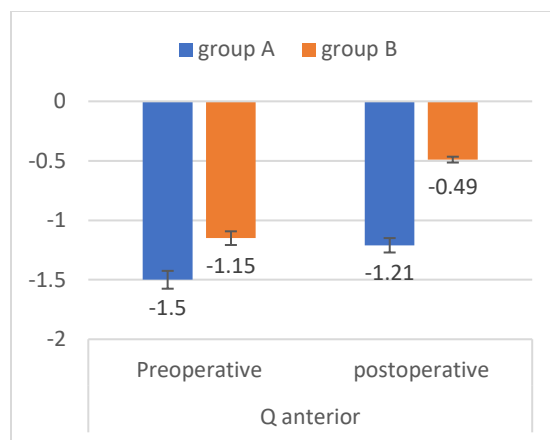


Figure (5): Comparison between the study groups regarding Q anterior

Discussion:

Our study results revealed that either implantation of single ring or double rings will have significant improvement of visual, refractive and keratometric values. However, these changes were more significant in Group b which has 2 rings. These results were similar to results of previous studies ^{9,10} In spite of this improvement the visual satisfaction of patients was variable as there is another factor which affect the visual satisfaction including the corneal asphericity which contributes to most of the spherical aberration of the eye⁵. In this study we focused on the effect of the ICRS on the corneal asphericity through studying the corneal asphericity coefficient (i.e., Q value). we found that the Q anterior in group A changes from preoperative mean -1.50 ± 0.61 to postoperative mean -1.21 ± 0.60 while in group B the changes were from preoperative mean -1.15 ± 0.44 to postoperative mean -0.49 ± 0.79 . The changes in group B were more toward normalization of the Q anterior which provide the least spherical aberration. As the Q value known to reduce the spherical aberration to nearly nil is -0.46 ¹¹.

As the nomograms present cannot predict the flattening effect of the rings exactly. it depends on the spherocylindrical refraction, cone location around the steep axis which are all objective ¹⁰. The nomograms provide the choice of the number, site, thickness and arc length of the rings so postoperative evaluation and clinical feedback is important to improve the results and visual satisfaction of the patients.

The number of rings used is still controversy inspite of various nomograms present¹². Utine et al studied the number of rings in comparison of asymmetric and central cones, there results revealed that double ring implantation were superior to

single ring as regard the corneal astigmatism, keratometry, and anterior corneal asphericity for central and partially asymmetrical however single ring was superior in totally asymmetrical cones².

In our study the effect of double ring on the corneal asphericity shows that this parameter should be considered in the choice of the number of rings implanted beside the cone location and spherocylindrical refraction.

Conclusion

Our results shows that corneal asphericity coefficient value should be considered in the choice of number of rings as the double rings shows more effect on the Q anterior toward normalization of the Q value to the ideal value which is -0.46 providing least spherical aberrations and hence more patient visual satisfaction

References

1. Kaya V, Utine CA, Karakus SH, Kavadarli I, Yilmaz OF. Refractive and visual outcomes after Intacs vs ferrara intrastromal corneal ring segment implantation for keratoconus: a comparative study. *J Refract Surg* 2011;27(12):907-912.
2. Utine CA, Özizmirli D, Kayabaşı M, Güneç Ü. The number of intracorneal ring segments in asymmetric and central cones. *Eye Vis (Lond)*. 2021 Mar 30;8(1):10. doi: 10.1186/s40662-021-00234-6. PMID: 33785054; PMCID: PMC8010988.
3. Giacomini NT, Mello GR, Medeiros CS, et al. Intracorneal ring segments implantation for corneal ectasia. *J Refract Surg*. 2016;32(12):829– 839
4. Mousa RM. Corneal asphericity changes after implantation of intracorneal ring segment (kerarings) in the treatment of Keratoconus. [NILES journal for Geriatric and Gerontology](#) April 2021, vol 4(Geriatric Ophthalmology):68-77. DOI:[10.21608/niles.2021.205502](#)
5. Utine CA, Ayhan Z, Durmaz Engin C. Effect of intracorneal ring segment implantation on corneal asphericity. *Int J Ophthalmol* 2018;11(8):1303-1307
6. Sakellaris D, Balidis M, Gorou O, Szentmary N, Alexoudis A, Grieshaber MC, et al. Intracorneal ring segment implantation in the management of keratoconus: an evidence-based approach. *Ophthalmol Ther*. 2019;8(Suppl 1):5–14.
7. Fernández J, Peris-Martínez C, Pérez-Rueda A, Hamida Abdelkader SM, Roig-Revert MJ, Piñero DP. Evaluation of a new nomogram for Ferrara ring

- segment implantation in keratoconus. *Int J Ophthalmol* 2021;14(9):1371-1383
8. Flecha-Lescún J, Calvo B, Zurita J, Ariza-Gracia MÁ. Template-based methodology for the simulation of intracorneal segment ring implantation in human corneas. *Biomech Model Mechanobiol*. 2018;17(4):923–38.
 9. Piñero DP, Alió JL. Intracorneal ring segments in ectatic corneal disease - a review. *Clin Exp Ophthalmol*. 2010;38(2):154–67.
 10. Vega-Estrada A, Alió JL. The use of intracorneal ring segments in keratoconus. *Eye Vis (Lond)*. 2016; 3:8.
 11. Manns F, Ho A, Parel JM, Culbertson W. Ablation profiles for wavefront-guided correction of myopia and primary spherical aberration. *J Cataract Refract Surg* 2002;28(5):766-774.
 12. Alió JL, Artola A, Hassanein A, Haroun H, Galal A. One or 2 Intacs segments for the correction of keratoconus. *J Cataract Refract Surg*. 2005;31(5):943–53.